

# Ophthalmology<sup>®</sup> *ROUNDS*

AS PRESENTED IN THE  
ROUNDS OF THE DEPARTMENT  
OF OPHTHALMOLOGY  
AND VISION SCIENCES,  
FACULTY OF MEDICINE,  
UNIVERSITY OF TORONTO

## Issues in the Management of the Anophthalmic Socket: Clinical, Comfort, and Cosmetic

BY MICHAEL C.F. WEBB, BADO, BCO, FASO

Ophthalmologists have many different perspectives on the terms “artificial eye” or “ocular prosthetic”. Indeed, it is not the last resort for enucleation and evisceration and, as the field of ophthalmology has advanced, so too has the relationship with ophthalmologists. To fully recognize enucleation and evisceration as a multidisciplinary approach is to offer patients the best option for a truly successful procedure. The role of the oculist does not end with the completion of the ocular prosthetic, and the involvement of an ophthalmologist does not end with the surgery to enucleate or eviscerate. To utilize the field of ophthalmology to its full potential is to understand the types of services and expertise available for the initial surgery and long-term care of the patient. This issue of *Ophthalmology Rounds* reviews the problems leading to an anophthalmic socket and the surgical and medical conditions involved in treating these difficulties.

### Enucleation and evisceration

A careful evaluation of these procedures may determine the long-term success for the patient, and the following list of preferences suggest the most desirable situations for ocular prosthesis or scleral lens success from the most preferred (top) to least preferred (bottom):

- Evisceration – hydroxyapatite (HA) pegged implant
- Enucleation – HA or porous polyethylene pegged implant
- Evisceration with implant
- Phthisis bulbi
- Enucleation – stable, centrally located sphere implants. Muscles attached in proper anatomical position.
- Enucleation – high-motility implants
- Microphthalmia
- Phthisis bulbi – exotropic or esotropic
- Dermis fat graft
- Enucleation – no implant
- Exophthalmos – lens to be fit over larger globe
- Congenital anophthalmia
- Contracted sockets – Grade 1-3
- Contracted, post-radiation sockets – Grade 4-5
- Orbital exenteration

The preferences relate to the incidence and severity of anomalies in the anophthalmic socket syndrome.<sup>1,2</sup> When choosing the procedures of enucleation and evisceration, it must be understood that evisceration is not always an option. The pre-existing condition of the eye due to either trauma or a tumour may dictate the procedure required. The fear of sympathetic ophthalmia is a consideration for enucleation;



FACULTY OF MEDICINE  
*University of Toronto*



Department of  
Ophthalmology and  
Vision Sciences

#### Department of Ophthalmology and Vision Sciences

Jeffrey Jay Hurwitz, MD, Editor  
*Professor and Chair*  
Martin Steinbach, PhD  
*Director of Research*

**The Hospital for Sick Children**  
Elise Heon, MD  
*Ophthalmologist-in-Chief*

**Mount Sinai Hospital**  
Jeffrey J. Hurwitz, MD  
*Ophthalmologist-in-Chief*

**Princess Margaret Hospital  
(Eye Tumour Clinic)**  
E. Rand Simpson, MD  
*Director, Ocular Oncology Service*

**St. Michael's Hospital**  
Alan Berger, MD  
*Ophthalmologist-in-Chief*

**Sunnybrook Health  
Sciences Centre**  
William S. Dixon, MD  
*Ophthalmologist-in-Chief*

**University Health Network  
Toronto Western Hospital Division**  
Robert G. Devenyi, MD  
*Ophthalmologist-in-Chief*

**Department of Ophthalmology  
and Vision Sciences,  
Faculty of Medicine,  
University of Toronto,**  
60 Murray St.  
Suite 1-003  
Toronto, ON M5G 1X5

The editorial content of  
*Ophthalmology Rounds* is determined  
solely by the Department of  
Ophthalmology and Vision Sciences,  
Faculty of Medicine, University of Toronto

however, the decision must relate to the individual circumstances. Sympathetic ophthalmia is not a definitive reason for enucleation without considering evisceration, since the potential for development is low if the eye is not enucleated, particularly given the current anti-inflammatory medications and ocular management techniques.<sup>3</sup> If the eye socket of the patient is relatively high on the list of preferences, it is less likely that anophthalmic socket syndrome anomalies will be a factor in fitting the ocular prosthetic.

### **Anophthalmic socket syndrome**

The anophthalmic socket syndrome or postenucleation syndrome encompasses several anomalies:<sup>2,4,5</sup>

- Superior sulcus deformity
- Ptosis
- Enophthalmos
- Ectropion with lax lower lid, or rarely, entropion

These anomalies are less frequent in the eviscerated socket than the enucleated socket, but they rarely occur following an evisceration.<sup>4</sup> Several key factors in an enucleation allow a good socket for fitting an ocular prosthesis. One is a sufficient posterior depth for the implant offering good closure of the overlying tissues.<sup>6</sup> Other factors are the size and design of the implant; for example, if the implant is too small, it contributes to enophthalmos, but if it is too large, it may restrict movement of the ocular prosthesis and may cause ptosis.<sup>7,8</sup> An excessively large implant will often restrict the depth of the prosthesis anterior chamber, giving the artificial eye an unnatural balance. This is particularly true if the prosthesis is a biointegrated style of implant such as HA or porous polyethylene.

The most common complications for patients with an ocular prosthesis after enucleation are recession of the upper lid sulcus, absence of the superior lid fold, and progressive enophthalmos.<sup>2</sup> These complications have been attributed to the degeneration of the inactive extraocular muscles, orbital fat atrophy, and the tendency for enophthalmos due to aging.<sup>9</sup> All of these factors should be considered when a decision must be made regarding either primary or secondary surgery.

### **Anophthalmic ptosis**

Anophthalmic ptosis is a situation requiring a separate classification because the anatomy varies in relation to the orbit contents, necessitating a wide range of implants, as well as various sizes of globes. However, the presence of a phthisical or microphthalmic globe is a contradiction for the anophthalmic ptosis classification.<sup>7</sup> In these situations, ocularists may sometimes repair a drooping lid by a change in the shape or volume of an ocular prosthesis or the scleral lens.

Surgeons handle ptosis corrections differently than ocularists. The ocularist is often expected to repair these situations prosthetically, but if this is impossible, then surgical correction is undertaken. If an appropriately fitted prosthesis can minimize the degree of correction required, surgical repair may be facilitated.

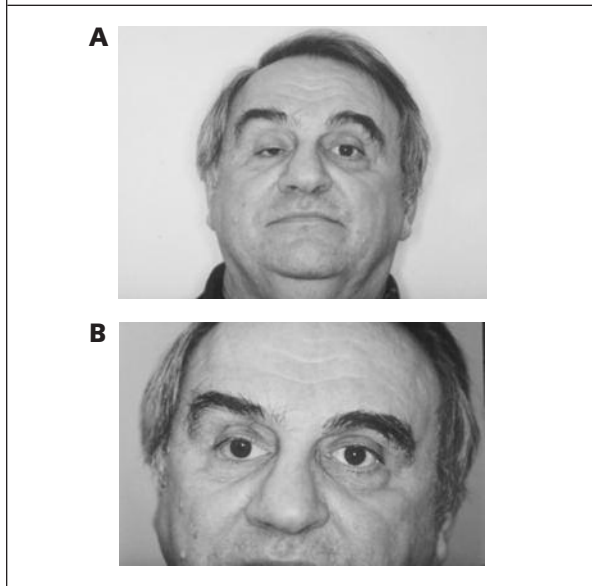### **Classification<sup>7</sup>**

- *Pseudoptosis* usually results from a lack of orbital volume, and often may be a result of microphthalmos, enophthalmos, phthisis, or a poorly fitted prosthesis. Pseudoptosis may also become apparent with a rapid regression of edema or an atrophy of the posterior orbital tissues (Figure 1A).
- *Persistent ptosis* is commonly attributed to accidental or surgical trauma (aponeurotic sheath attached to the levator muscle becomes disinserted). There may also be myogenic, neurological, or congenital causes. As well, a superiorly migrated sphere that causes the levator muscle and tarsus to be pushed forward and downward may produce a ptosis.
- *Temporary ptosis* most commonly occurs after enucleation or evisceration during the first few weeks to several months. It is usually caused by edema of the orbital tissues pressing the upper edge of the tarsus forward; subsequently, the upper lid moves anteriorly or inferiorly. Infection, inflammation, and steroid myopathy also result in this type of ptosis.
- *Intermittent ptosis* may often be secondary to a medical problem such as transient Horner syndrome, myasthenia gravis, or third-nerve paralysis. Waking or morning ptosis may also be intermittent ptosis and pseudo-intermittent types of ptosis may result from protein deposits on the surface of the prosthesis. Fatigue-type ptosis results from the exhaustion of the levator muscle and is also intermittent.
- *Progressive ptosis and pseudoptosis* may be the result of a familial ptosis such as blepharophimosis or a tumour in the orbit. A growing tumour will usually manifest in a progressive manner. Atrophy of the posterior orbital fatty tissues or rapid regression of edema may also manifest itself as progressive ptosis.<sup>7</sup>

### **Prosthetic correction**

After the assessment and classification of an anophthalmic ptosis, a prosthetic correction is undertaken (Figure 1B). At this point, relatively few options are available for an ocularist. The 2 main components for correction are a ptosis shelf or a ptosis crutch; both options have merits and limitations. A ptosis shelf is the most effective and recommended method of correction for those patients with normal lid function (Figure 2A). The superior portion of the ocular prosthesis is redesigned and cut away approximately 11 mm superiorly, allowing

**Figure 1:** A patient with pseudoptosis before (A) and after (B) prosthetic correction



an alteration of the position of the tarsal plate in relation to the cut away section of the prosthesis, thus elevating the lid.

A ptosis crutch is more functional cosmetically and structurally for neurological causes or third-nerve paralysis (Figure 2B). A ptosis crutch creates a physical obstruction on the anterior surface of the prosthesis that supports the upper lid. If an ocularist assesses and/or refits the prosthesis prior to surgery, the results of ptosis correction are maximized. A pseudoptosis is often present; therefore, appropriate prosthetic fitting may eliminate the need for surgery, or at least minimize the degree of correction.

### Contracted sockets

Contracted sockets offer difficult management problems for the ocularist and the oculoplastic or ophthalmic surgeon, and management is best approached as a team. Understanding the mechanics and anatomy of both the normal and contracted

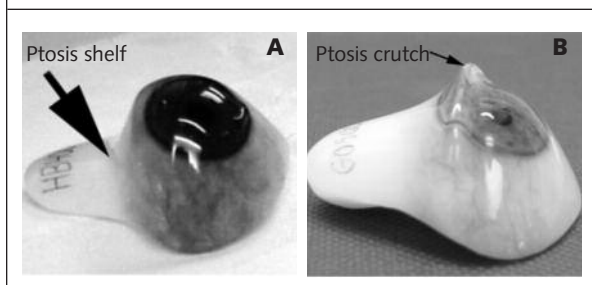
socket is crucial and identifying realistic goals is critical. To positively identify these goals, both the ocularist and the ophthalmologist must fully understand the other's capabilities. Most importantly, the patient's needs and desires should be fully explored, since the lack of communication between all involved frequently results in failure and/or disappointment.

An ocularist has several options or devices available to deal with contractions and/or the contracted socket; however, to completely understand the options, proper categorization of the condition will assist in determining the type of correction, both prosthetically and surgically. The following is a classification of contracted sockets.<sup>10</sup>

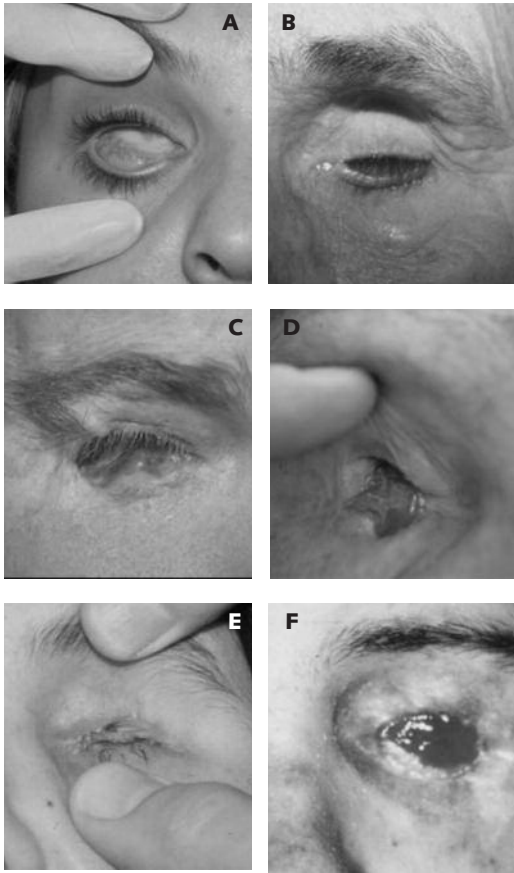
- **Grade 0:** The socket is lined with a healthy conjunctiva and has deep and well-formed fornices (Figure 3A).
- **Grade 1:** The socket is characterized by a shallow lower fornix or shelving of the lower fornix. In this case, the lower fornix is converted into a downwards sloping shelf that pushes the lower lid down and out, preventing retention of an artificial eye (Figure 3B).
- **Grade 2:** The socket is characterized by the loss of the upper and lower fornices (Figure 3C).
- **Grade 3:** The socket is characterized by the loss of the upper, lower, medial, and lateral fornices (Figure 3D).
- **Grade 4:** The socket is characterized by the loss of all fornices and reduction of the palpebral aperture in horizontal and vertical dimensions (Figure 3E).
- **Grade 5:** In some cases, there is recurrence of contraction of the socket after repeated trial of reconstruction (Figure 3F).

This is an excellent format for classification from the ophthalmology point of view; however, minor changes to this classification are suggested for ocularists. Grades 3 and 4 are very similar (loss of all fornices), but a distinction is made about the loss of the palpebral aperture or a diminished fissure. If all fornices are contracted, there is almost invariably a diminished palpebral fissure. Grade 5 makes no attempt to characterize the condition of the fissures, only that the recurrence of contraction occurred postoperatively. Grades 4 and 5 often occur after radiotherapy. Grade 5 represents loss of all fornices due to contraction postoperatively, after surgery completed within the last year, achieving an unsuccessful result. After 1 year, if nothing is done surgically or prosthetically to this socket to correct this situation, it should be reclassified as Grade 4. Thus, Grade 5 indicates a recent failed attempt at socket reconstruction; this is important because many surgeons prefer to wait a specific period of time before making a second attempt at full reconstruction, usually a full year.

**Figure 2:** Prosthesis with ptosis shelf (A), and ptosis crutch (B).



**Figure 3:** Contracted sockets Grade 0 (A), Grade 1 (B), Grade 2 (C), Grade 3 (D), Grade 4 (E), Grade 5 (F).

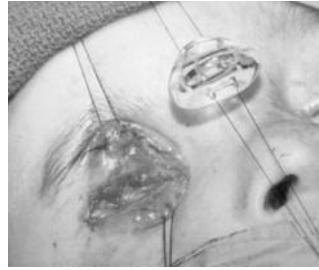


There are several management tools, both prosthetically and surgically, in the management of contracted sockets. The most effective for a Grade 3, 4, or 5 is the custom design conformer (CDC; Figure 4);<sup>11</sup> however slight modifications are often necessary. First, the design should be custom-made for the individual patient and local ocularists can usually supply at least 3 progressively sized CDCs. The objective is to understand

**Figure 4:** A custom design conformer (CDC).



**Figure 5:** Superior and inferior anchoring sutures are aligned.



both the dynamics of the socket, the surgical approach, and the desired realistic result. The socket should be designed from a realistic surgical approach both in size and graft availability. An ocularist can design the multiple CDCs based on this configuration. The socket reconstruction is not designed for a device, the device should be designed for the socket (Figure 5). Once the design is chosen, the conformer is lined with buccal mucous membrane (Figure 6). Two superior and inferior fornix-deepening sutures of 4-0 braided polyester are passed through the lids and tied over bolsters.<sup>12</sup> In more severe cases, as in Grade 3 or 4, it is advisable to pass sutures through superior and inferior holes in the conformer then through the periosteum to securely fix the conformer in position.<sup>12</sup>

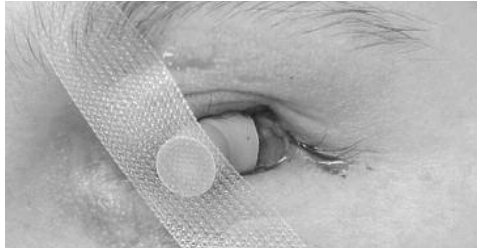
Once the surgery is complete and the CDC is anchored properly, the role of the ocularist is critical, since the future success of this operation may depend on their skills. The CDC is usually ready for removal 6-12 weeks after its insertion, depending on the classification of the socket. The best option to is to remove the sutures and free the conformer, but not fully remove it. At this point, the ocularist should be prepared to insert a new custom conformer designed for that particular socket to help maintain the fornices. There should be no time lapse between removal of the

**Figure 6:** An oral mucous membrane is attached to the CDC and sutured into the socket.

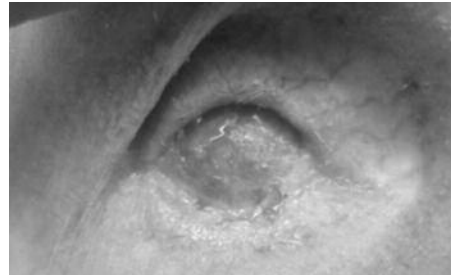




**Figure 7:** A capillary traction device is taped in the socket under pressure.



**Figure 9:** A contracted socket Class 3.



CDC and the insertion of the new conformer. Failure to adhere to this principle will compromise the potential success of the surgery.


The ocularist is also required to instruct the patient in several methods of pressure treatment for the socket that will help possible future post-operative contractions of this socket. Allowing a CDC or ocular prosthesis to remain out of the socket at any time up to 1 year after this surgery will almost invariably result in a cicatricial contraction of the socket or the complete loss of the ability to retain an ocular prosthesis by the reconstructed socket.

Several methods of postoperative management of the contracted socket are available for ocularists. The most successful are the capillary traction device (Figure 7) and the Lafuente pressure mask (Figure 8).<sup>13</sup> The first device offers several options; for instance, the design allows proactive management of the socket by utilizing the pressure at night. This method also allows the pressure to be applied on active cicatricial contraction in the socket, which can often be critical to the success or failure of the reconstructed socket.

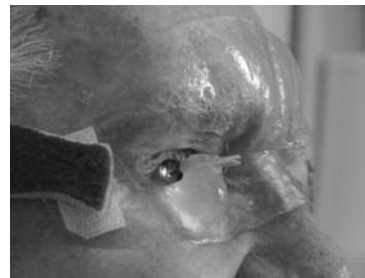
If it appears that the socket is contracting and the ability of the fornices to retain a device or ocular prosthesis may be lost (Figure 9), the next option is to make a Lafuente pressure mask. The design of this mask allows a more concentrated pressure focus with a compensating spring or

elastic that adapts to the fluctuating cicatricial contraction (Figure 10). A pressure stent is applied to one or both fornices or a custom conformer is mounted on the pressure stent to force this socket to adapt to the shape of the desired conformer. This may often be the last resort or manoeuvre by the ocularist to retain a conformer or, subsequently, an ocular prosthesis, as shown in this final result (Figure 11). Leaving the mask on for 20-60 minutes can create a sufficient fornix to retain a prosthesis in situations when the retension is crucial. Open lines of communication must be maintained between the ocularist and the ophthalmologist for the best possible chance of success in these difficult cases. Fortunately, it is a rare circumstance that a

**Figure 8:** A Lafuente pressure mask.



**Figure 10:** A contracted socket management utilizing a Lafuente pressure mask.



**Figure 11:** The prosthesis is successfully retained and fitted using a Lafuente pressure mask in the patient shown in Figures 9 and 10.



prosthesis cannot be satisfactorily fitted, leaving the following options:

- Remove all of the orbital soft tissue and fit an osseointegrated prosthesis
- Remove all of the orbital soft tissue and attach an orbital prosthesis to glasses or use adhesives to attach to skin
- Allow the socket to fully contract and wear dark glasses or a black patch

## Conclusion

The complete understanding of the field of ophthalmology by the ophthalmologist is imperative for success in utilizing an effective multidisciplinary approach. The benefits to the patient of this team approach are immeasurable. Prior to any type of reconstructive surgery or modification of the anophthalmic socket, the prosthesis should be in its optimum condition. The ophthalmologist can assess this condition as well as make any modifications necessary; this may minimize the degree of surgical correction required or completely eliminate the need for surgery.

---

*Mr. Webb is President, Webb Ocular Prosthetics, Inc., Toronto, Ontario, and Member, Board of Directors, Canadian Society of Ocularists.*

---

## References

1. Workman CL. Prosthetic reduction of upper eyelid ptosis. In: Bosniak SL, Smith BC, eds. *The Anophthalmic Socket*. New York, NY: Pergamon Press; 1990:184-191.
2. Vistnes LM, Iverson RE, Laub DR. The anophthalmic orbit. Surgical correction of lower eyelid ptosis. *Plast Reconstr Surg*. 1973;52(4):346-351.
3. Lindsey RN, Soper MP. Sympathetic ophthalmis following evisceration: a review of the literature. *The Journal of the American Society of Ocularists*: 1977-1996; 17<sup>th</sup> Edition. St. Petersburg, FL: ABI Professional Publications: 28-30.
4. Spaeth PG. Superior sulcus deformity and ptosis. In: Shannon GM, Connelly FJ, eds. *Oculoplastic Surgery And Prosthetics*. Boston, MA: Little, Brown and Company; 1970:791-797.
5. Cowen DE, Antonyshyn O. The vascularized temporoparietal fascial flap for correction of the deep superior sulcus. *Ophthalm Plast Reconstr Surg*. 1995;11(2):100-108.
6. Jahrling RC. Prosthetics for upper lid deformities. In: Shannon GM, Connelly FJ, eds. *Oculoplastic Surgery And Prosthetics*. Boston, MA: Little, Brown and Company; 1970:813-822.
7. Allen L. Reduction of upper eyelid ptosis with the prosthesis, with special attention to a recently devised, more effective method. In: Guibor P, Guibor M, eds. *Techniques of Anophthalmic Cosmesis*. New York, NY: Symposia Specialists; 1976:3-25.
8. Allen L. The argument against imbricating the rectus muscles over spherical implants after enucleation. In: Bosniak SL, Smith BC, eds. *The Anophthalmic Socket*. New York, NY: Pergamon Press; 1990: 184-191.
9. Kennedy RF. Effects of enucleation on socket anatomy. *Journal of Ophthalmic Prosthetics*. 1997;2(1):43-46.
10. Krishna G. Contracted sockets-1 (aetiology and types). *Indian J Ophthalmol*. 1980;28(3):117-120.
11. Harrington JN. Conformer design. *The Journal of the American Society of Ocularists*. 1979;10:11-14.
12. Molgat YM, Hurwitz JJ, Webb MCF. Buccal mucous membrane-fat graft in the management of the contracted socket. *Ophthalmic Plast Reconstr Surg*. 1993;9(4):267-272.
13. Scott R. C.T.D.: A unique suction device. *The Journal of the American Society of Ocularists*. 1986;17:11-14.

## Upcoming Scientific Meetings

26 – 29 June 2010

**Canadian Ophthalmological Society 2010**

**Annual Meeting and Exhibition**

Québec, Quebec

CONTACT: E-mail: [cos@eyesite.ca](mailto:cos@eyesite.ca)

Website: [http://www.eyesite.ca/annualmeeting/2010/index\\_e.php](http://www.eyesite.ca/annualmeeting/2010/index_e.php)

## University of Toronto

**Department of Ophthalmology and Vision Sciences**

## Upcoming events

4 – 5 December 2010

**Update in Ophthalmology 2010**

CNIB Centre, 1929 Bayview Avenue

Toronto, Canada

## For Further Information:

Office of Continuing Education & Professional Development

Faculty of Medicine, University of Toronto

TEL: 416.978.2719/1.888.512.8173

FAX: 416.946.7028

E-mail: [info-OPT1002@cepdtoronto.ca](mailto:info-OPT1002@cepdtoronto.ca)

Website: <http://www.cepd.utoronto.ca>

---

**Disclosure Statement:** Mr. Webb has stated that he has no disclosures to announce in association with the contents of this issue.

Change of address notices and requests for subscriptions for *Ophthalmology Rounds* are to be sent by mail to P.O. Box 310, Station H, Montreal, Quebec H3G 2K8 or by fax to (514) 932-5114 or by e-mail to [info@snellmedical.com](mailto:info@snellmedical.com). Please reference *Ophthalmology Rounds* in your correspondence. Undeliverable copies are to be sent to the address above. Publications Post #40032303

---

This publication is made possible by an unrestricted educational grant from  
**Novartis Pharmaceuticals Canada Inc.**

---

© 2010 Department of Ophthalmology and Vision Sciences, Faculty of Medicine, University of Toronto, which is solely responsible for the contents. Publisher: SNELL Medical Communication Inc. in cooperation with the Department of Ophthalmology and Vision Sciences, Faculty of Medicine, University of Toronto. *Ophthalmology Rounds* is a registered trademark of SNELL Medical Communication Inc. All rights reserved. The administration of any therapies discussed or referred to in *Ophthalmology Rounds* should always be consistent with the approved prescribing information in Canada. SNELL Medical Communication Inc. is committed to the development of superior Continuing Medical Education.